Management of Brachial Plexus & Peripheral Nerves Blast Injuries

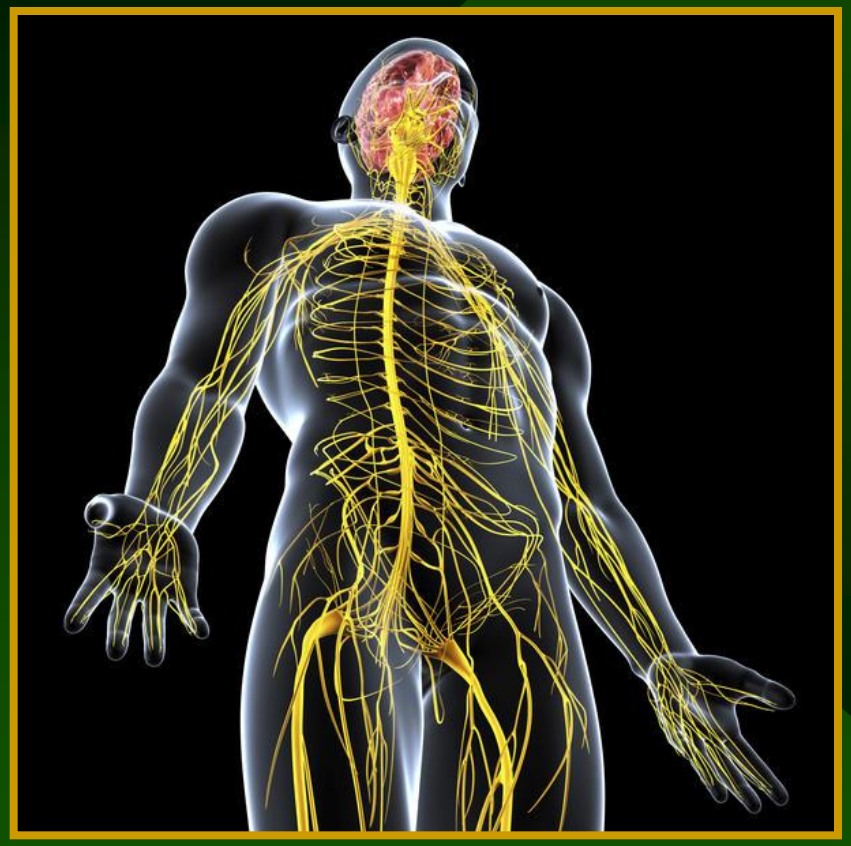

Joseph BAKHACH

First Global Conflict Medicine Congress

Hand & Microsurgery Department
American University of Beirut Medical Centre

1866 AUB American University of Beirut الجامعة الأميركية في بيروت

Brachial plexus blast injury

- ⟶ Three trunks
- ⟶ Six divisions
- ⟶ Three cords

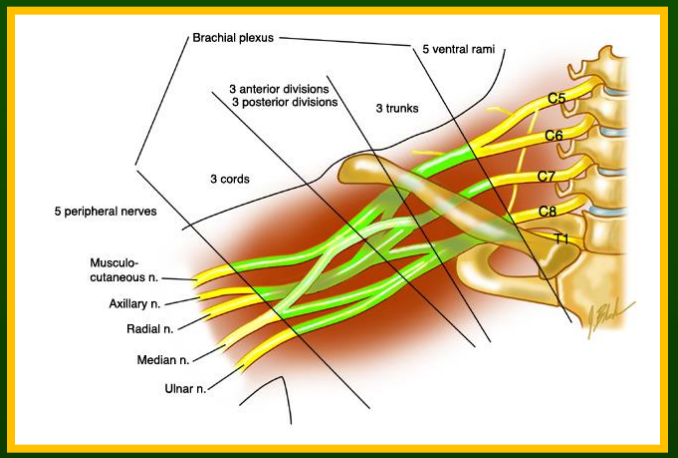

Peripheral nerves blast injury

- Median nerve
- Ulnar nerve
- Radial nerve
- Musculo-cutaneous nerve
- Axillary nerve
- Sciatic nerve
- Tibialis nerve
- Common peroneal nerve

  Etc…..

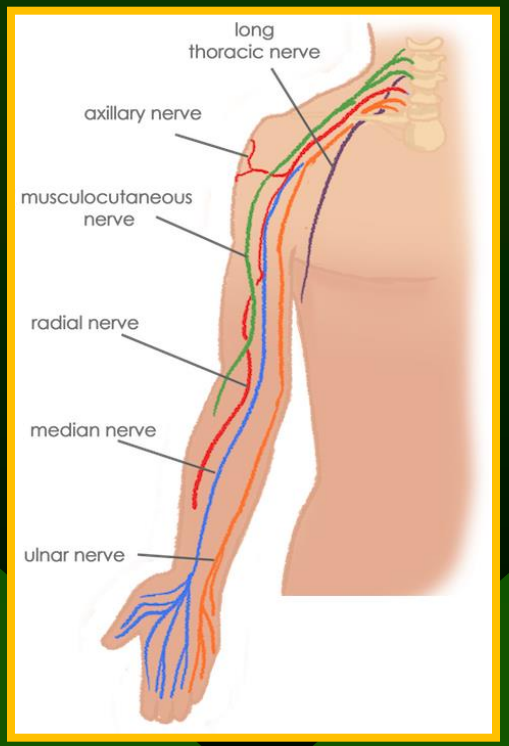

Main difference between nerves civilian and war injuries

- **Type of the injury**

Extent of the injury

Time of presentation

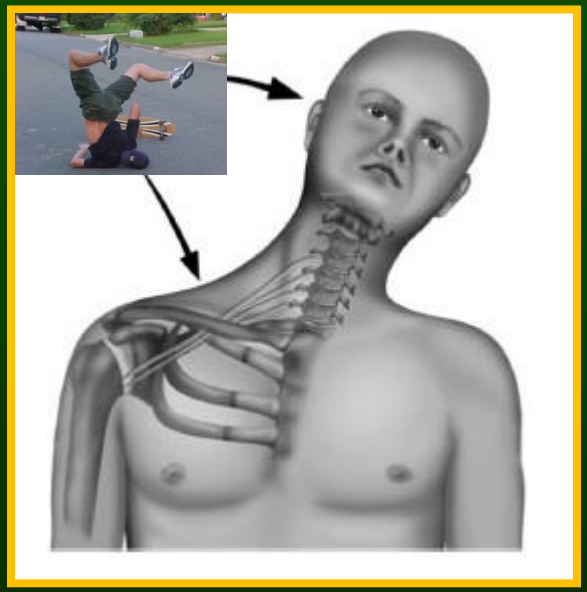

Brachial injuries in MVA are traction, compression and/or avulsion of the roots from the spinal cord

Blast and penetrating injuries cause traction, compression and nerve rupture. The "shock wave" component & thermal dissipation of the blast cause damage beyond the entry/exit trajectory of the projectile enlarging the zone of damage.

Main difference between nerves civilian and war injuries

- Type of the injury
- **Extent of the injury**
- Time of presentation

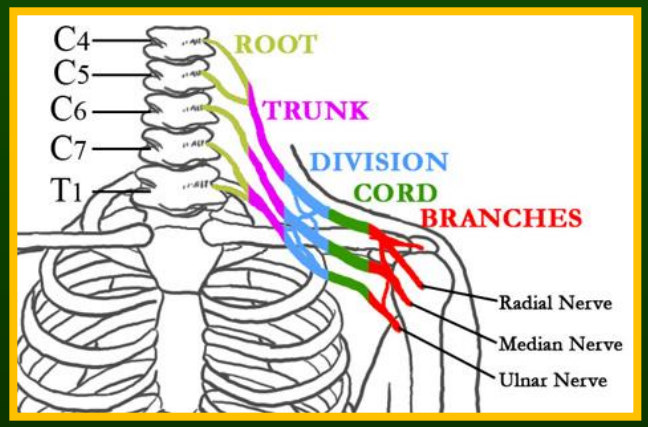

Injuries are well defined by the level of the injury (upper, lower brachial plexus, trunk and cords) and their treatments are well standardized

Blast injuries are commonly associated to bone fractures (clavicle, ribs, scapula, etc…) and fragmented bones may become secondary missile causing damage along their proper trajectory different from that of the original blast

Main difference between nerves civilian and war injuries

- Type of the injury
- Extent of the injury
- **Time of presentation**

In acute situation, procedures are performed to save a war-injured patient's life or limb. Microsurgeons are not usually consulted, brachial plexus injuries are not mapped and nerves stumps are not marked for easier subsequent exploration and repair.

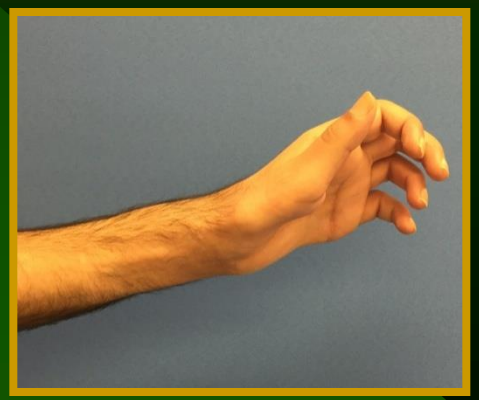

Investigations to be performed before embarking into the treatment process

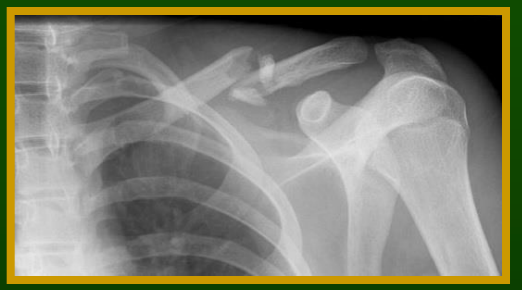

- Plain radiograph
  - **Reveals fractures and their states of healing, presence of foreign bodies**
- CT Scan
  - **Evaluate fractures, localizes foreign bodies and reveals presence of collection**
- CT angiography
  - **Evaluation of the vascular system if any suspicion of thrombosis or fistula**
- Magnetic Resonance Imaging
  - **Can show the roots, trunks, divisions & cords. Foreign bodies = limitations.**
- Electromyography
  - **Imperative in diagnosis and follow-up. To be done after 4 weeks from the injury**

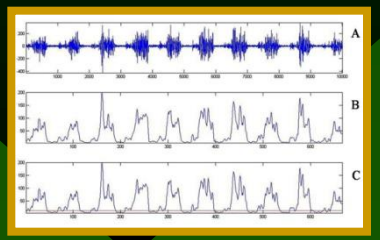

26-year-old male presented 2-months after a bullet penetrating injury to his right brachial plexus

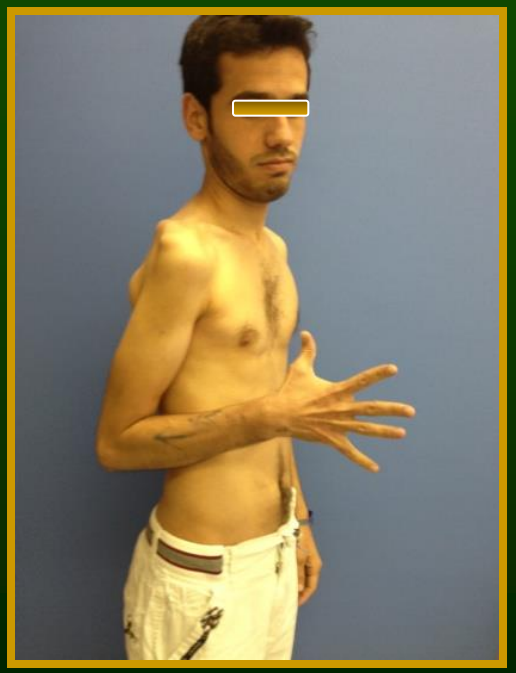

- Physical examination & EMG at 8 weeks :
  - → Total lesion of the right axillary nerve
  - → Partial lesion of the right musculocutaneous, suprascapular,
  - → lateral and posterior cords

Neurologist suggested to repeat the EMG in two months

- Physical examination & EMG at 12 weeks showed the same lesions with no improvement & no collateral reinnervation

Decision for surgical exploration was taken

Total exploration of the right brachial plexus from the supra-clavicular (trunks) to the infa-clavicular zones (divisions & cords)

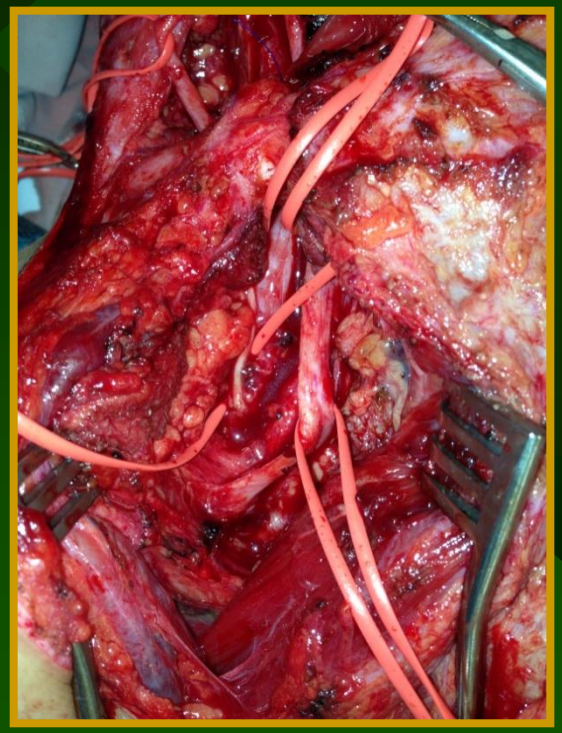

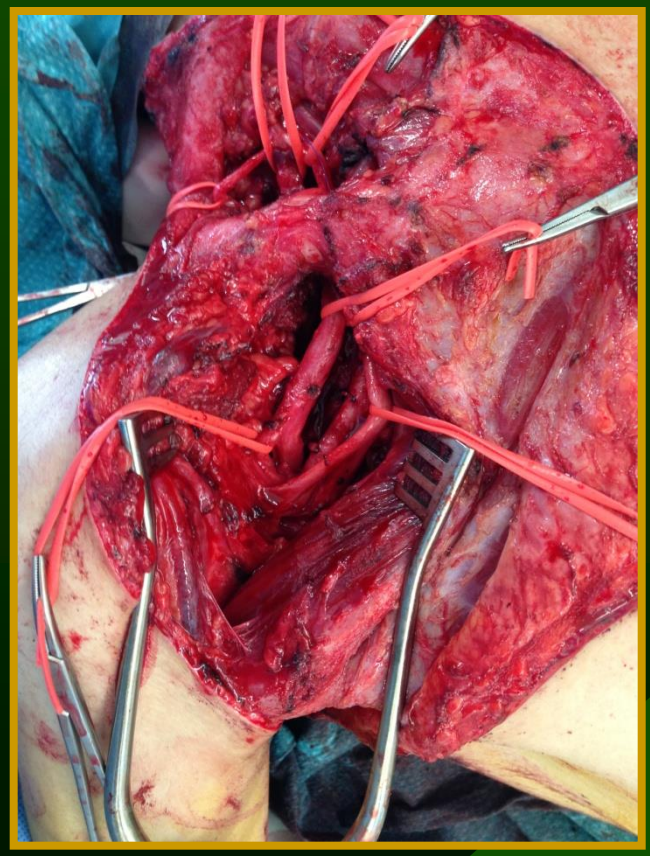

An organized fibrotic compressive hematoma was found and the different elements of the brachial plexus were released

Six months postop, the patient recovered a near-normal function with an efficient abduction of the shoulder

30-year-old male presented 3-months after a gunshot injury to his right axilla and shoulder

- Patient underwent a revascularization of his upper arm with a subclavian shunt and a surgical exploration of his right brachial plexus in outside hospitals which ended with no nerve repair.

- Physical examination & EMG at 12 weeks :
  - → Total deficit of the Median & Ulnar nerves
  - → Lesion of the musculocutaneous
  - → Lesion of the medial & the lateral cords

Decision for surgical exploration

Total exploration of the right brachial plexus which showed the interruption of the medial cord & the MC nerve to its origin on the lateral cord, with a compressive fibrosis of the lateral and the posterior cords

Total release of the lateral & posterior cords with nerve grafting of the medial cord and the musculocutaneous nerve.

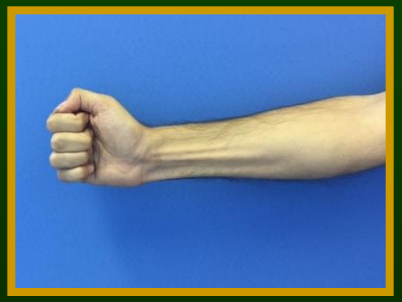

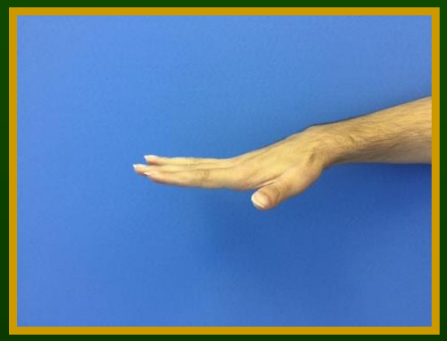

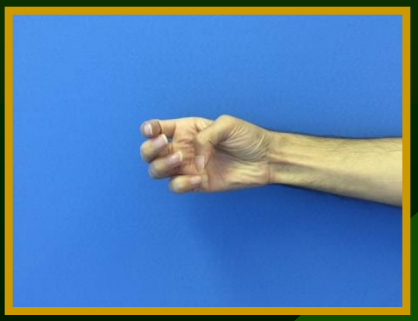

18-months post-operative, patient recovered a near-normal function of his shoulder, elbow flexion and hand motions

Nerve transfer or neurotization consists on taking a nerve from its original muscle «less important» and inserted into a different «more important» muscle whose nerve supply has been damaged.

- **Accessory to suprascapular nerve**
- **Triceps branch to axillary nerve**
- **Ulnar to musculocutaneous nerve**
- **Intercostals to musculocutaneous nerve**

Muscle and tendon transfer consists on transferring a functional muscle to a new position where it can perform the function of the denervated muscle.

- **LD mucsle to forearm for elbow flexion**
- **Trapezius muscle for shoulder abduction**

52-year-old male presented with a left upper trunk, lateral cord and axillary nerve injuries, 6-months after having a blast injury to his left shoulder

- In spite of the brachial plexus repair and nerve grafting, the patient did not recover the full function of his left arm and still having a deficit of his elbow flexion and shoulder abduction.

- The management plan consisted:
  - → Trapezius muscle transfer for shoulder abdcution
  - → Ulnar to musculocutanous nerve neurotization for elbow flexion

In the donor ulnar nerve, a mapping of the different fascicules is done and the antero-medial or the antero-lateral fascicule is selected depending on their action on the Flexor Carpi Ulnaris mucsle

Donor nerve

Recipient nerve

On the recipient nerve “musculo-cutaneous”, the motor branch dedicated to the biceps muscle should be only neurotized.

Result after 4-month follow-up

Result after 8-month follow-up

As the nerve connection is very close to the end muscle plates, the muscle contraction normally should start few weeks after the neurotization.

Once the nerve transfer is stabilized and the nerve regeneration is in process, the trapezius transfer for shoulder abduction can be performed

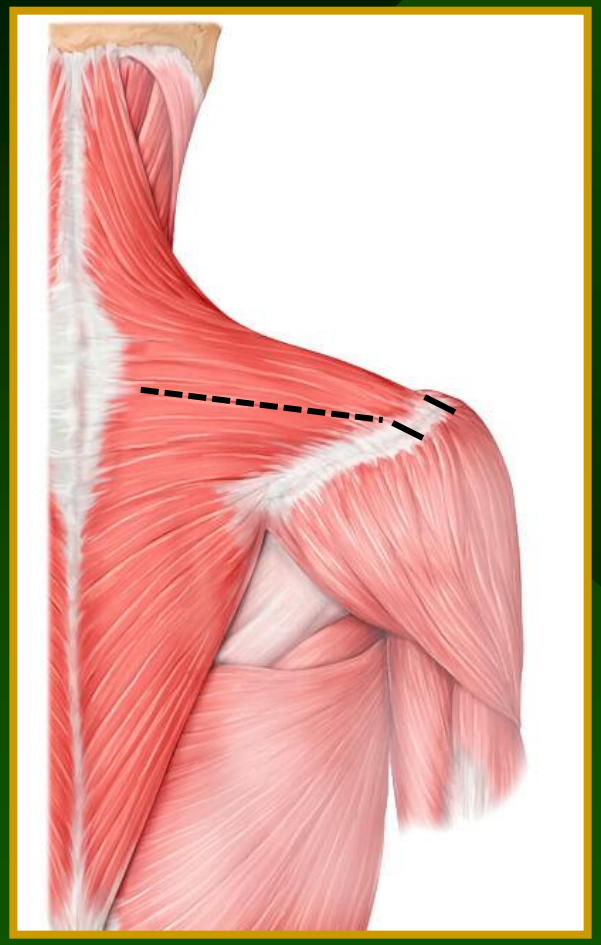

Upper part of the trapezius muscle
Prolonged by the acromion bone
→ less then 3 cm of width
→ more stable humeral fixation
→ orientation of the muscle action

Result after 12-months follow-up with elbow flexion to 150 degrees and a shoulder abduction to 90 degrees providing a good function to the left upper arm.

As for the war brachial plexus injuries, peripheral nerves penetrating injuries have some specificities when compared to the civilian nerve injuries

- Type of the injury
  - Laceration, traction and rupture are usually encountered.
  - We do not have to minimize the effect of shock wave and thermal dissipation
- Extent of the injury
  - Rarely it is a single nerve injury, unless it is a penetrating shrapnel or bullet injury
  - Most of the time is a complex and composite injury (bone, muscle, vessel, skin, etc…)
- Localization of the injury
  - Any peripheral nerve can be injured and always many nerves are involved
- Time of presentation
  - Most of the patients who presented to us are in the sub-acute or chronic phases having joint contracture, skin deformity, tendons adhesions and muscles starting to atrophy.

Shrapnel injury to the deep motor branch of the left ulnar nerve in a 26 year-old-man

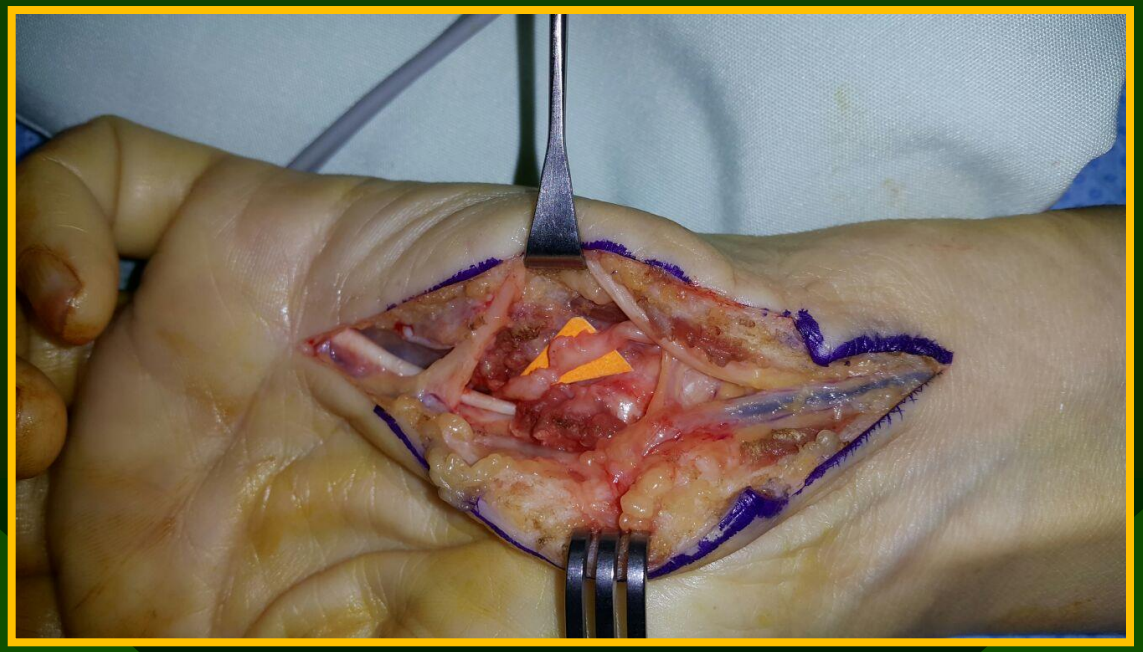

A neuroma of the Ulnar motor branch was revealed before the entrance of the nerve into the deep hand compartment

Shrapnel injury to the deep motor branch of the left ulnar nerve in a 26 year-old-man

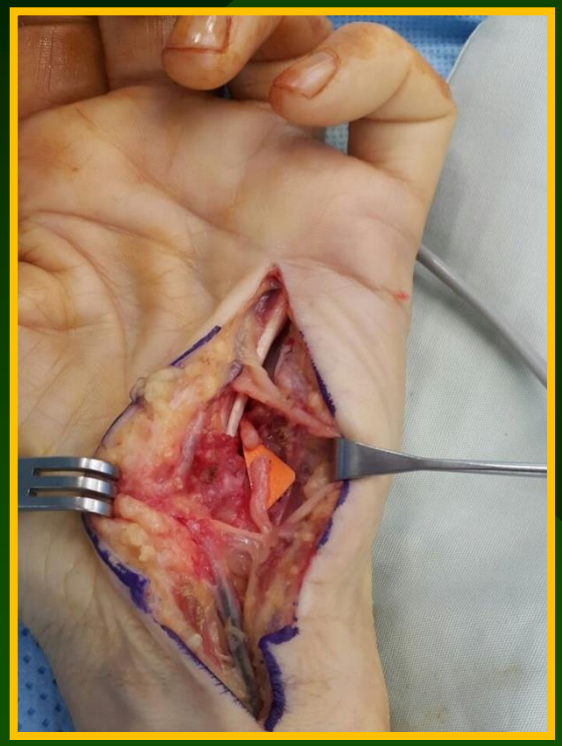

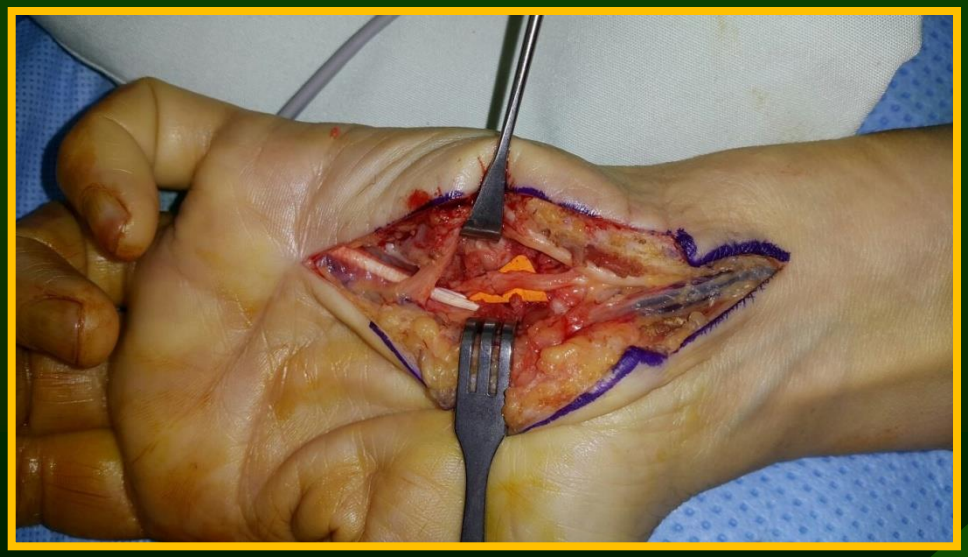

The neuroma of the Ulnar nerve motor branch was excised followed by the direct approximation of the stumps

Shrapnel injury to the deep motor branch of the left ulnar nerve in a 26 year-old-man

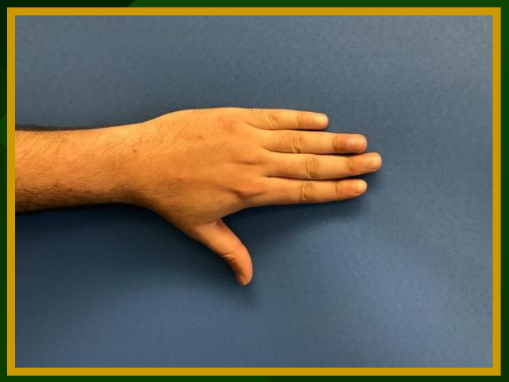

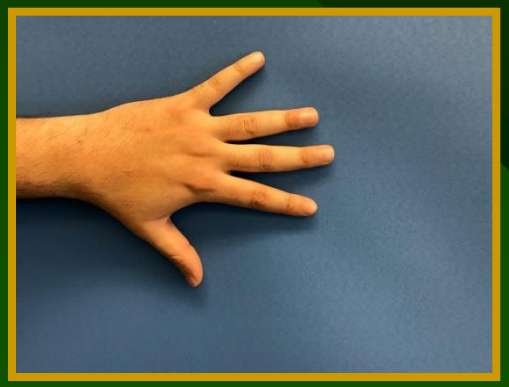



Results after 5-months follow-up with restoration of the inter-osseous muscles activity and disappearance of the Froment sign

Bullet injury to the left wrist with total laceration of the median nerve in a 42 year-old-man

The patient presented to us two years after the initial injury after multiple surgeries to his median nerve with total insensate fingers, thenar muscles atrophy and contracture of the first web space

Bullet injury to the left wrist with total laceration of the median nerve in a 42 year-old-man

The first web space was totally released and fixed with two inter-metacarpal Kirschner wires.

The median nerve exhibits a defect of 5 cm which was grafted using three cables.

Bullet injury to the posterior aspect of the right thigh with injury to both divisions of the sciatic nerve in a 36 year-old-man

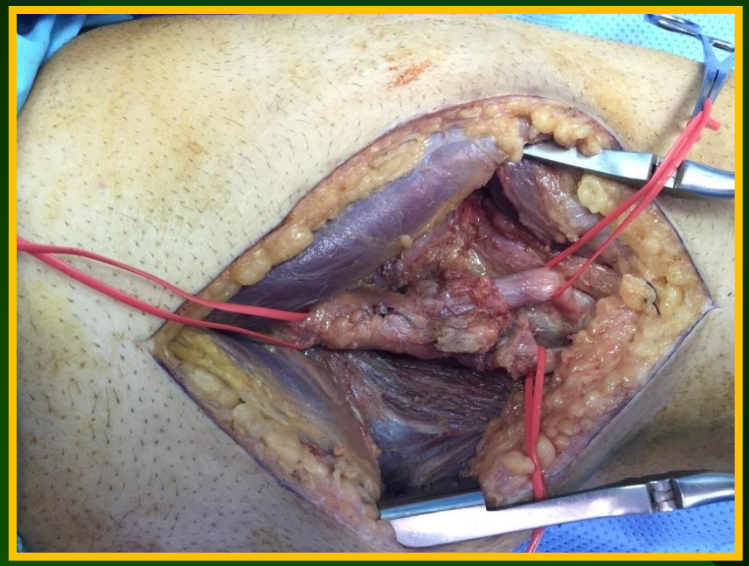

Neuroma in continuity of the tibial nerve
Total transection of common fibular nerve – peroneal nerve

Neuroma excision / nerve graft of the common fibular nerve
Neurolysis of the tibial nerve

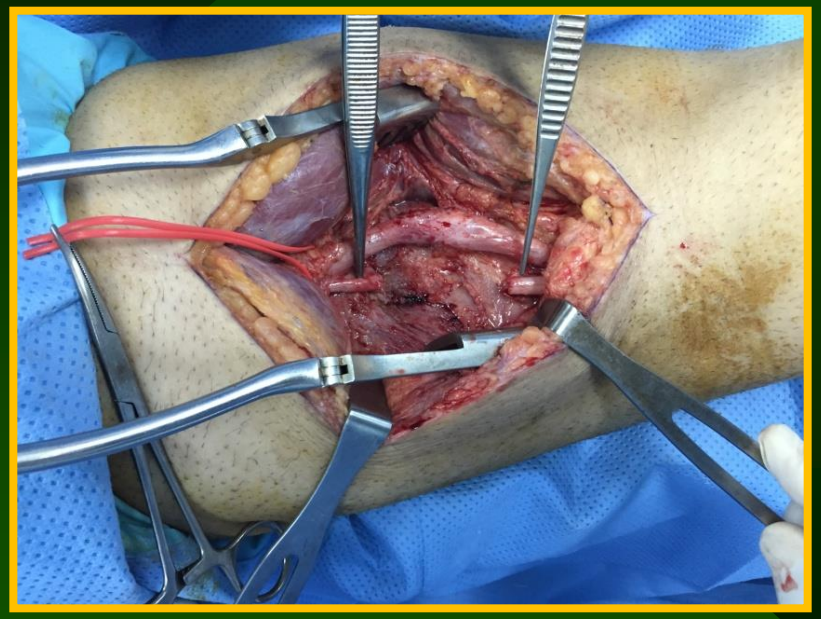

Patient recovered a normal plantar flexion with drop foot deformity which was corrected later on by tendon transfer

Shrapnel injury to the medial side of the left ankle in a 40 year-old-man

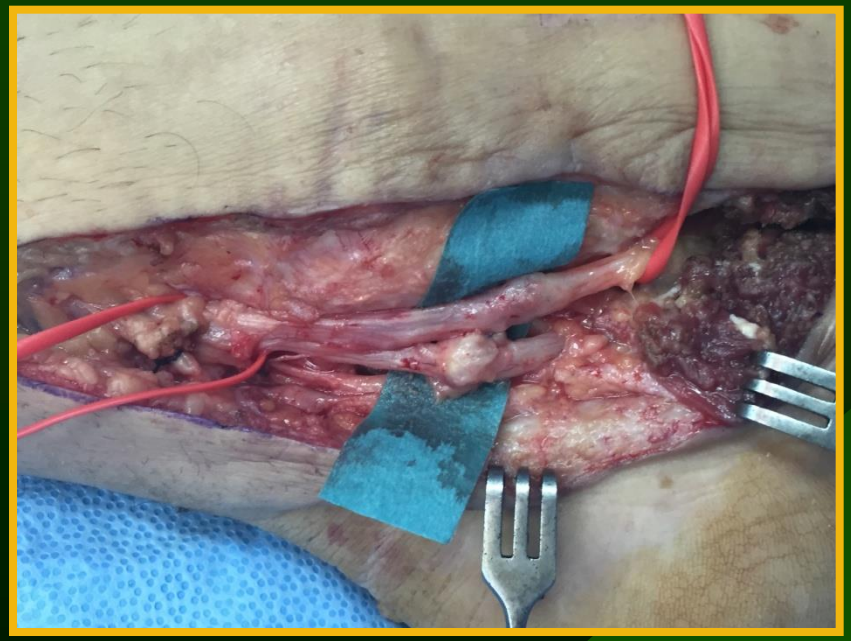

Neuroma in continuity of the medial division of the posterior tibial nerve with total transection of the lateral division of the posterior tibialis nerve

Neuroma excision and direct repair of the lateral branch
Neurolysis of the medial branch

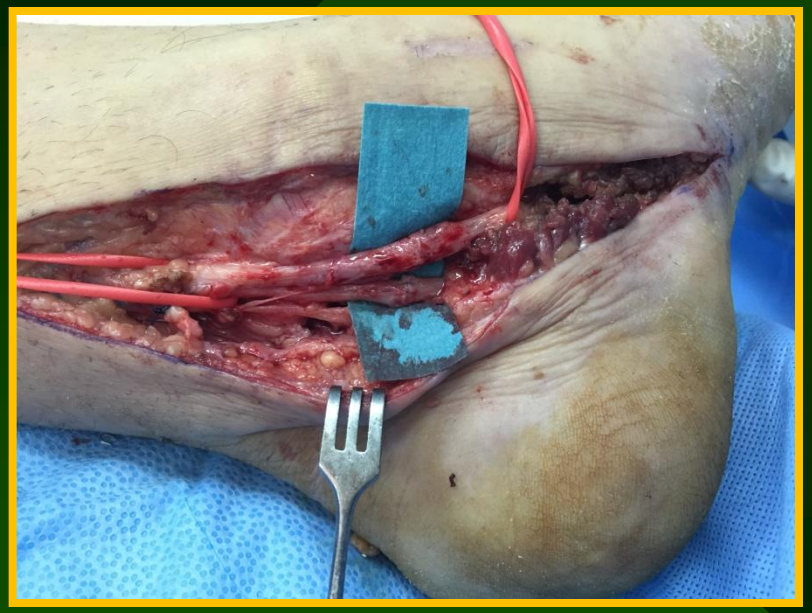

Patient recovered a protection sensation of his plantar zone and a near normal toes function with total disappearance of the tingling

Neuroma of the Posterior Tibialis Nerve stuck to the scar of a foot stump

Foot amputation at the ankle level

Neuroma excision and nerve positionning in the inter-osseous space.

Tendons transfers for Radial Nerve Palsy

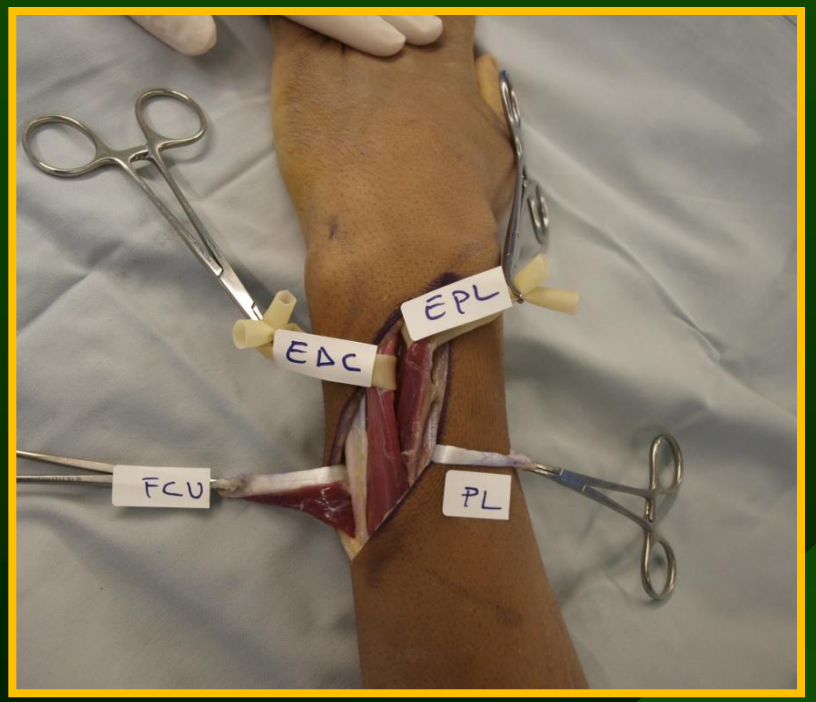

- **Reanimation of fingers extension**
- **Reanimation of thumb extension**

→ **FCU to EDC**

→ **PL to EPL**

Tendons transfers for Radial Nerve Palsy

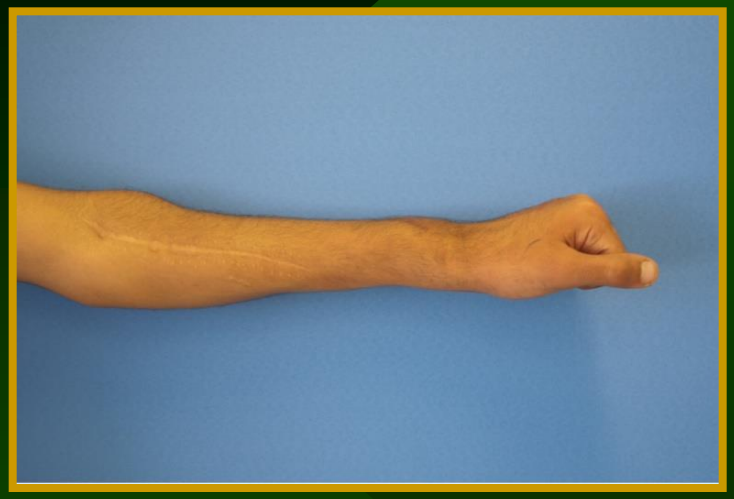

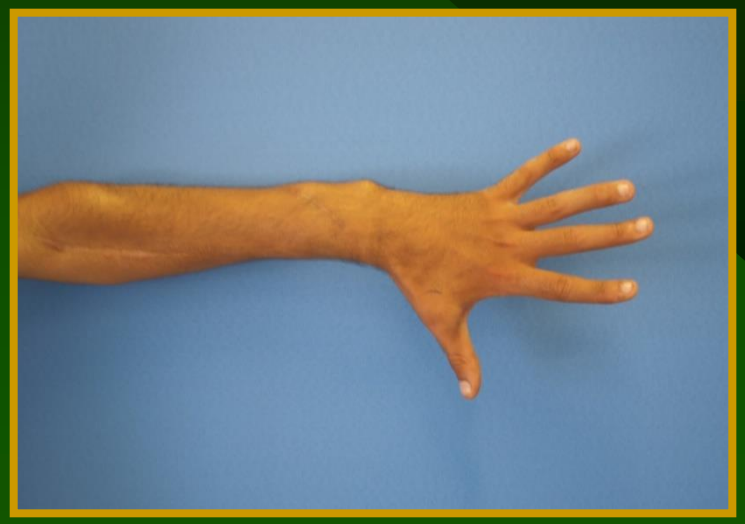

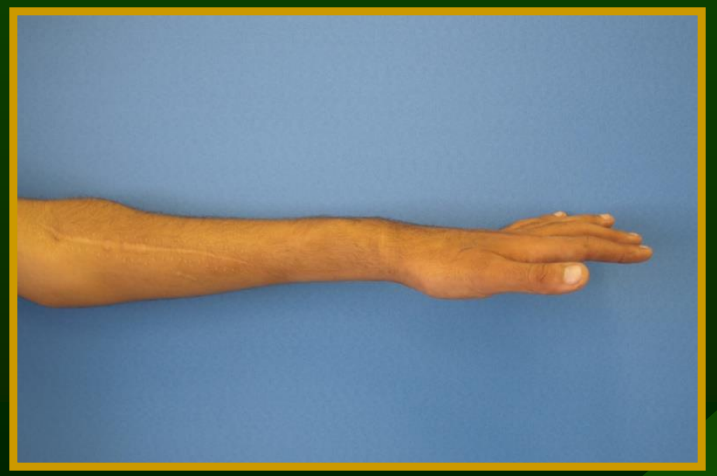

Tenodesis phenomenon

Should we graft a nerve even if the chances of recovery are very poor ?

List the different conditions for nerve repair

- **Site of injury**
- **Age & occupation of the patient**
- **Type of injury: single or composite**
- **Timing of repair: primary, secondary or delay**
- **Extent of nerve injury**

Yes, we have to excise the neuroma and graft the gap

- **Protective sensation**
- **Neuropathic pain**

CONCLUSION

Do not hesitate to be aggressive particularly when no signs of collateral re-innervation occur and we still in the period of active muscle endplates

- Real diagnosis of nerve compression or rupture
- To perform the adapted treatment
- To give the best chances for physiological recovery

In the situation of muscles already atrophied, tendons and muscles transfers should be considered