# Abdominal wall reconstruction

Ari Leppäniemi
Abdominal Center
Meilahti hospital
University of Helsinki
Finland

# Planned hernia with early skin-grafting

# Massive ventral hernia

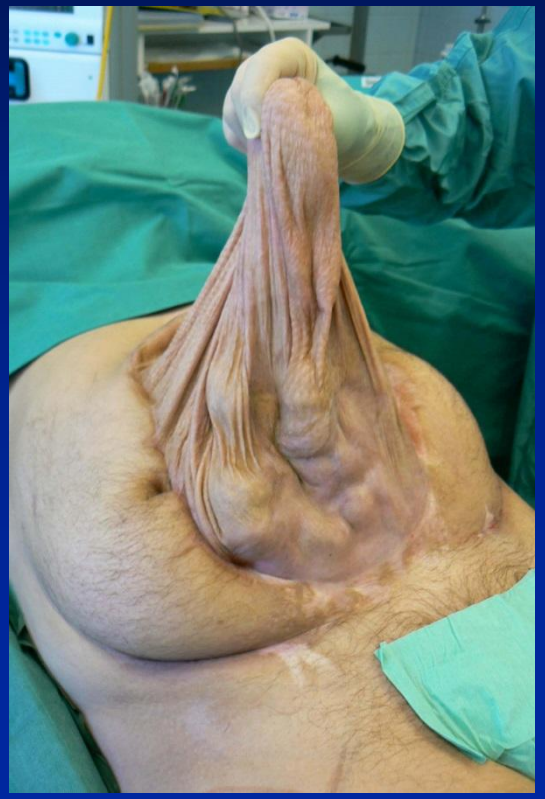

# Planned hernia

- fascial defect with original skin cover
  - fascial replacement (mesh)
  - fascial approximation (component separation)
  - combination

- fascial and skin defect

# Components separation (Ramirez et al. 1990), originally described by Albanesi 1951

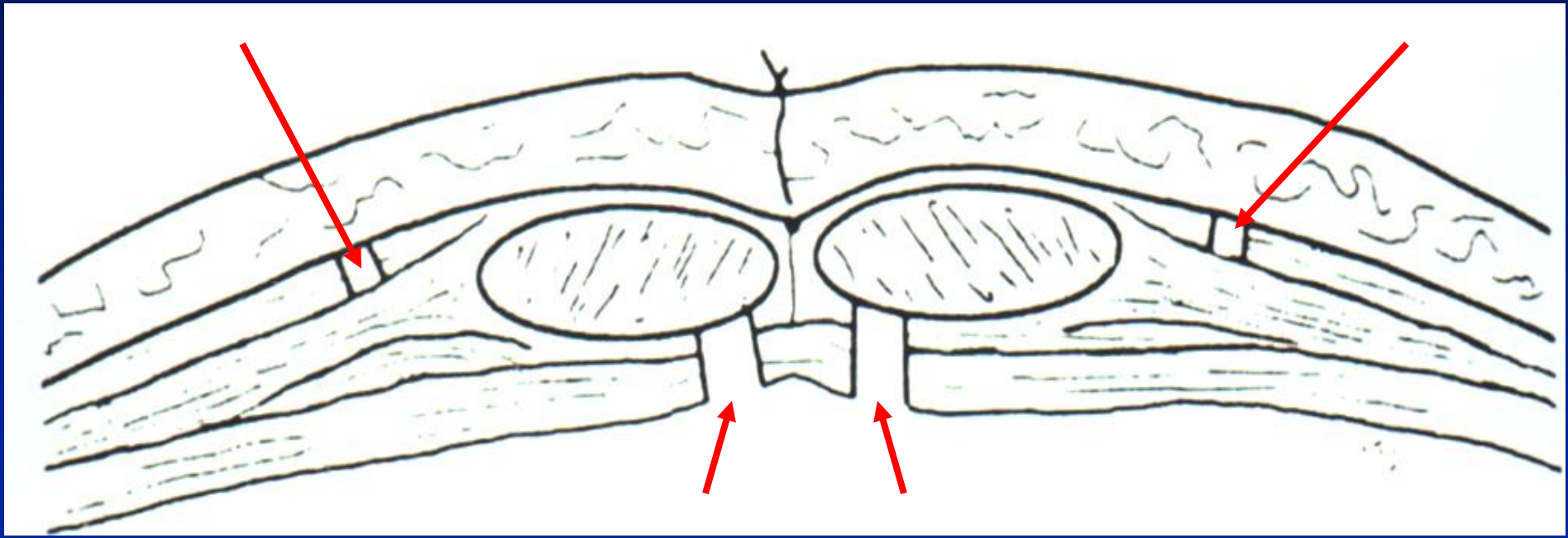

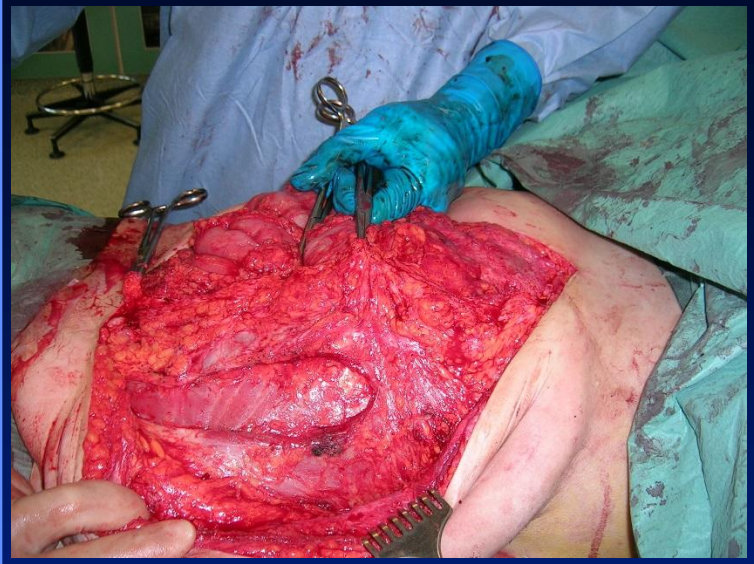

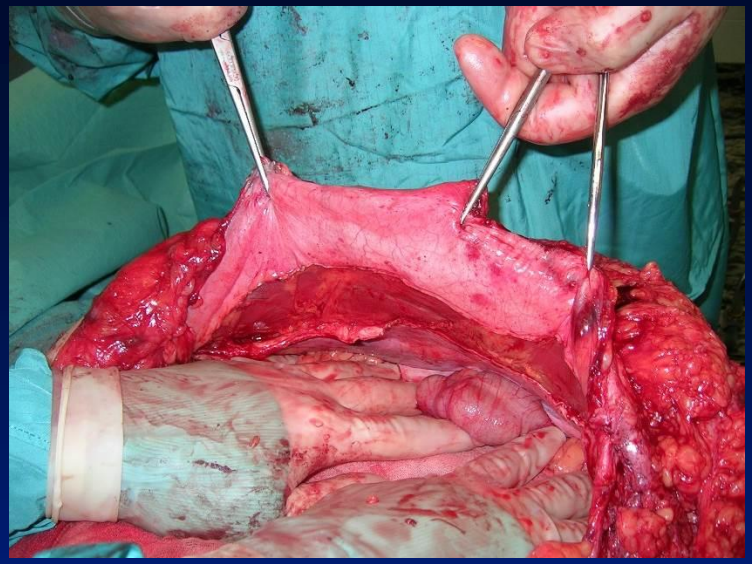

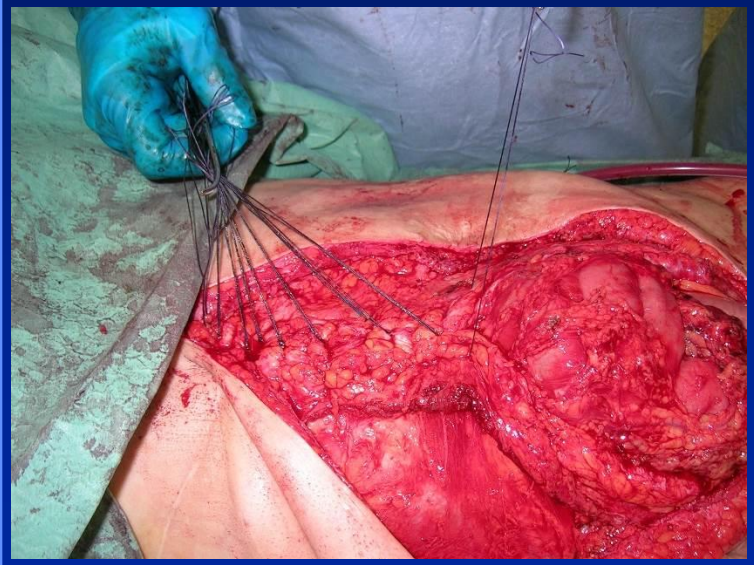

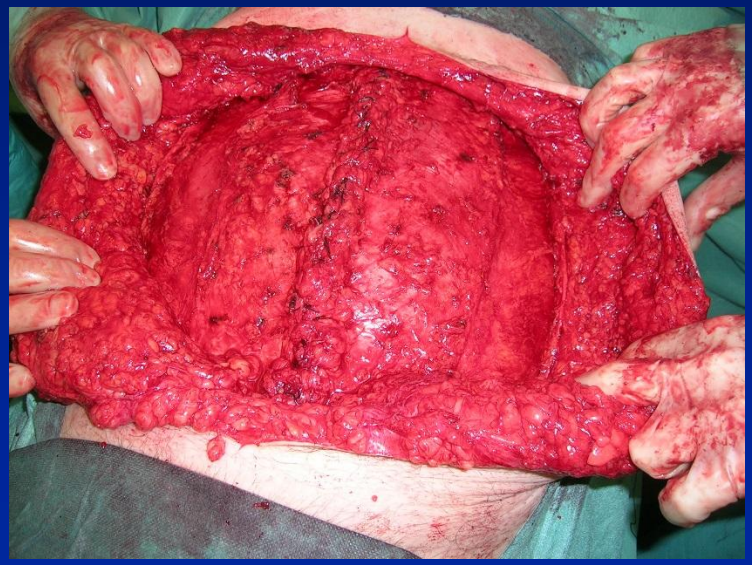

# Mini-invasive components separation

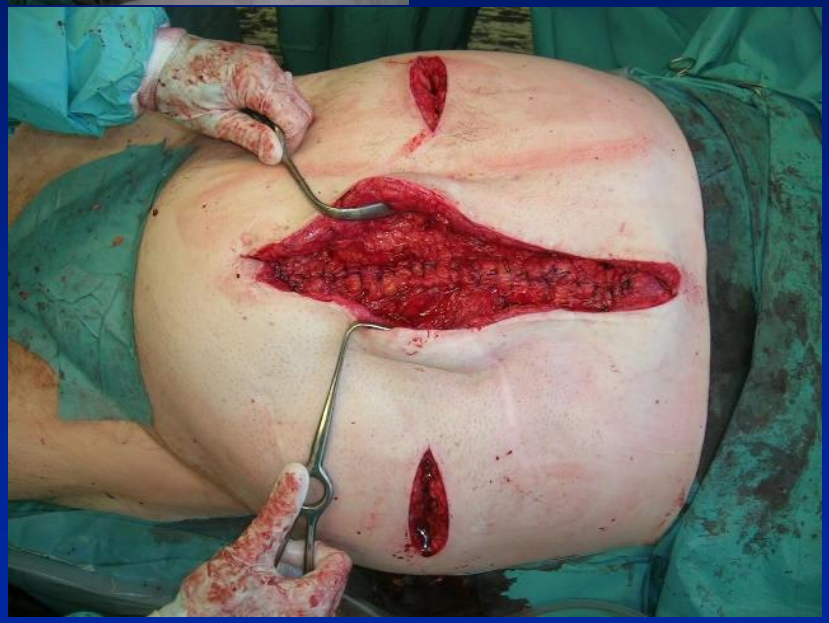

# Mesh repair

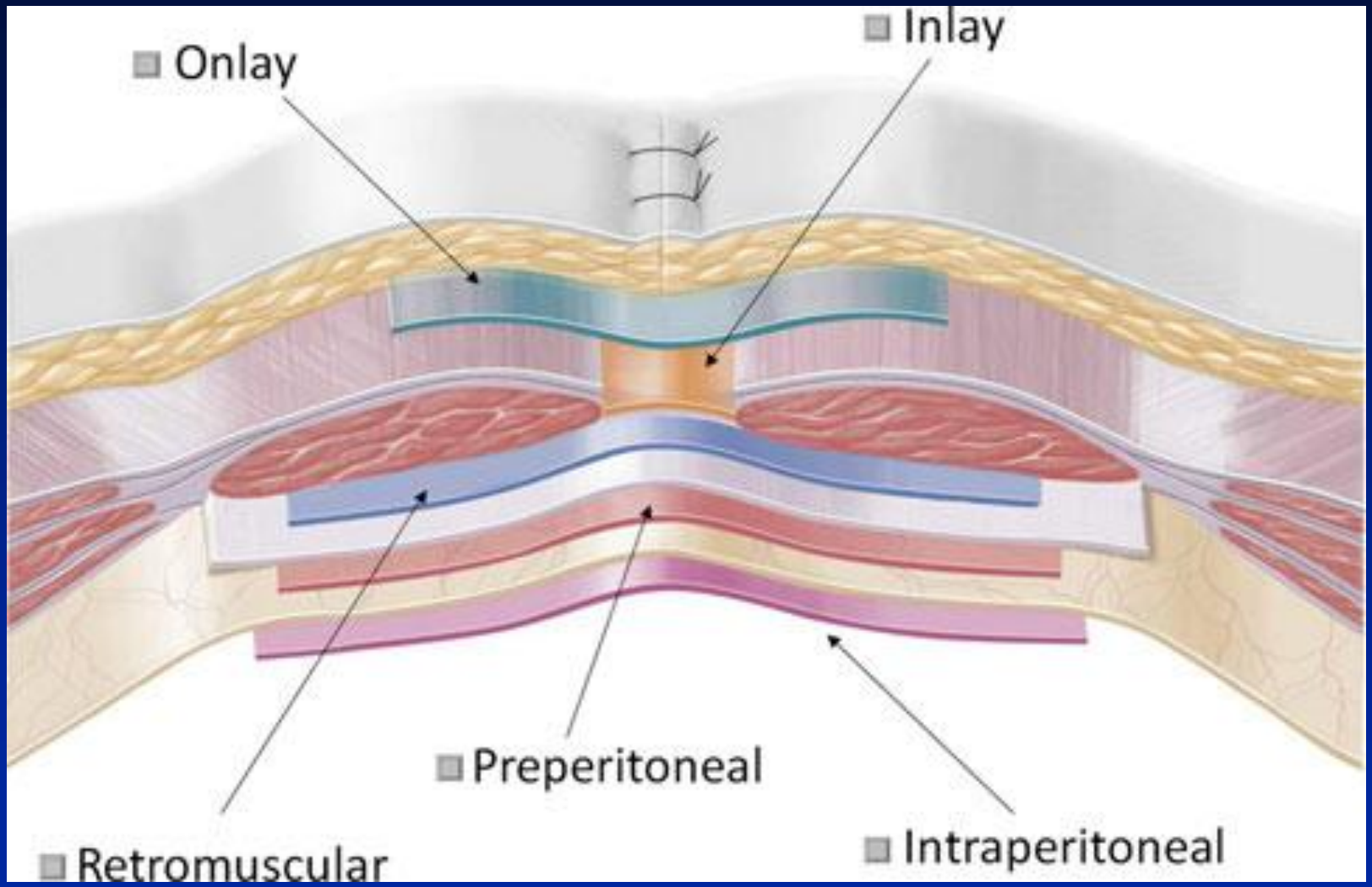
Onlay
Inlay
Preperitoneal
Retromuscular
Intraperitoneal


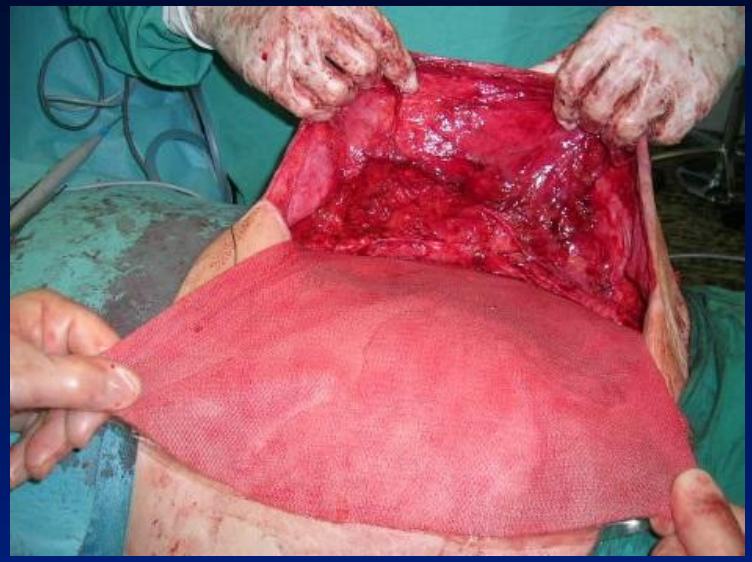

# Biological meshes

- partially remodeling prostheses
  - porcine dermal collagen, human dermal collagen, bovine pericardium collagen
- completely remodeling prostheses
  - porcine intestinal mucosa

- different remodeling times
- resistance to mechanical stress (partially remodeling meshes)
- low adhesiogenic power ?
- resistance to infection (contamination) ?

# Prosthesis or CST ?

- randomized study, n=39, follow up 36 months
  - e-PTFE (PR) vs. components separation (CST)
- PR (n= 18), CST (n=19), no in-hospital mortality

| | PR | CST |
|---|---|---|
| Wound complications | 13 | 10 |
| Prosthesis removed for infection | 7* | n/a |

* 30-262 days later, defect corrected with CST

| | | |
|---|---|---|
| Reherniation | 4 | 10 |

- delay mean 22 vs. 7 months, smaller after CST

de Vries Reilingh et al. WJS 2007

# Component separation + mesh

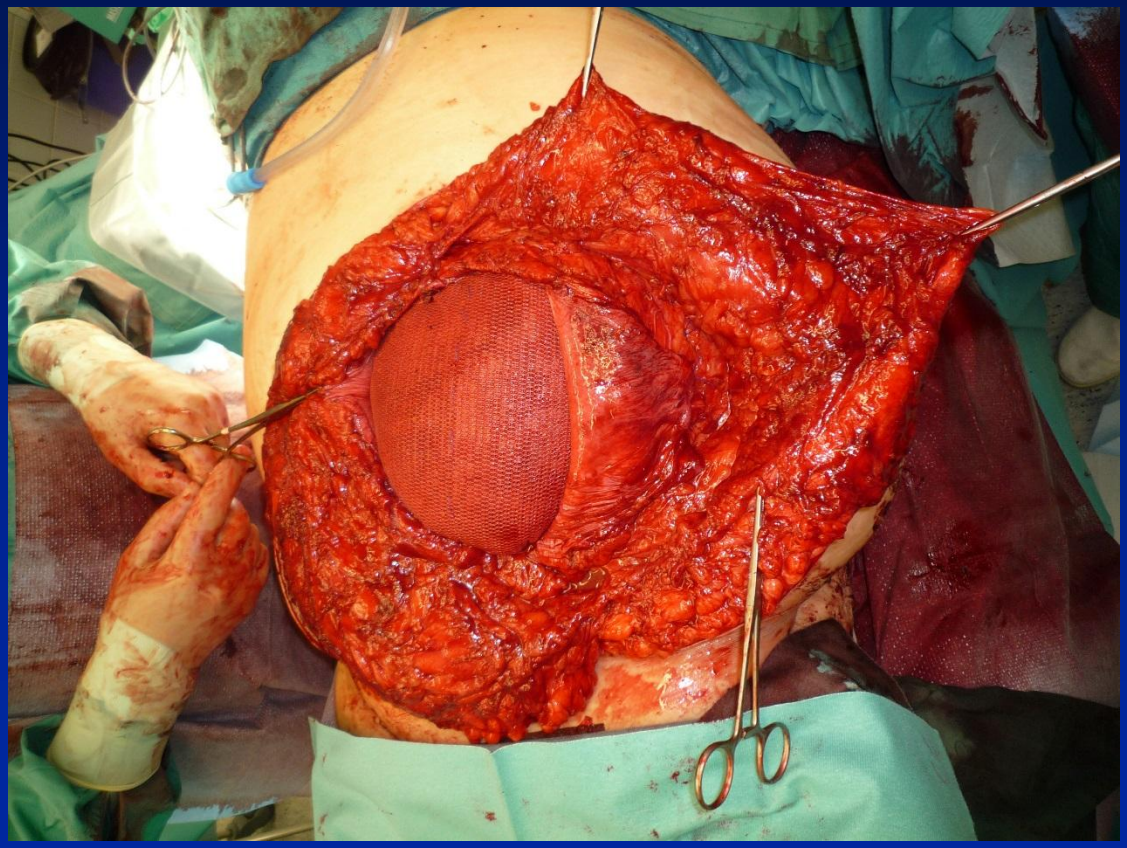

# Planned hernia

- fascial defect with original skin cover

- fascial and skin defect
  - split-thickness skin graft
  → late abdominal wall reconstruction

# Planned hernia with early skin-grafting


# Maturation of the skin graft

When it is ready

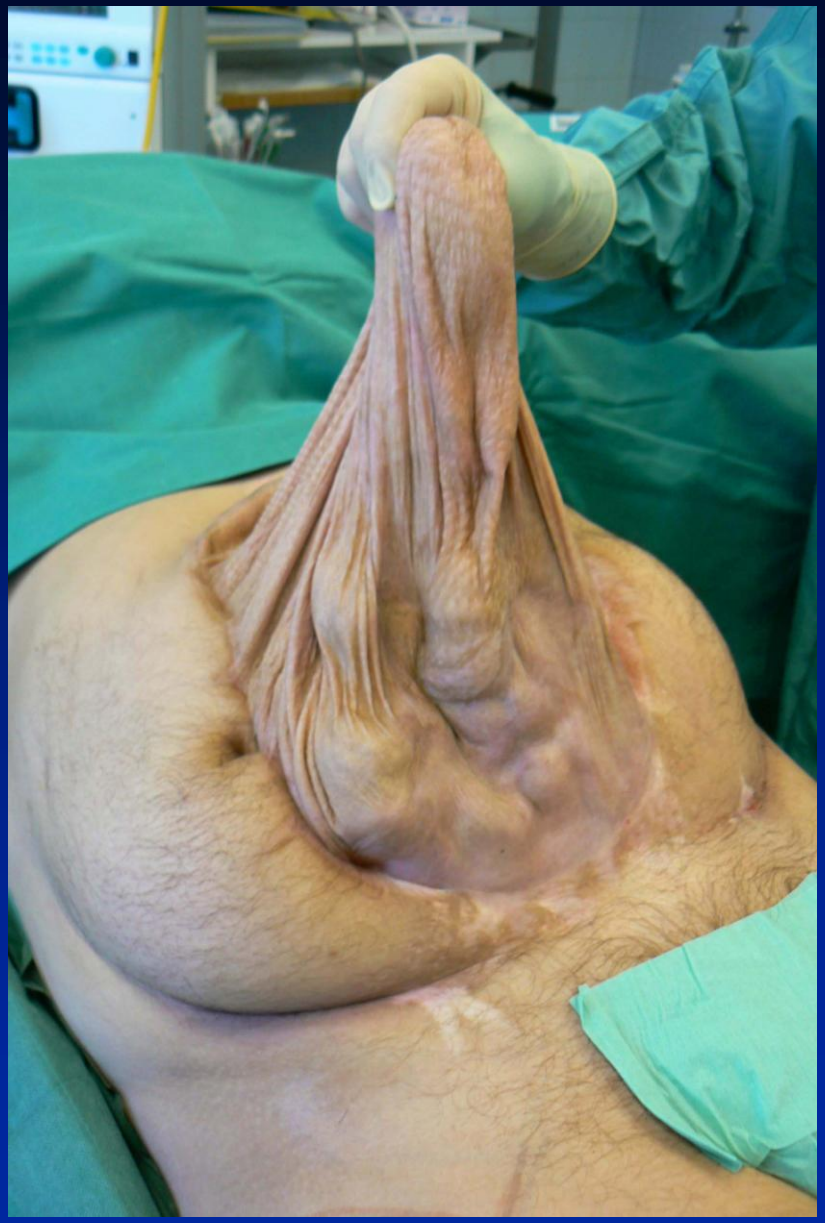

# Abdominal wall reconstruction with Tensor fascia lata (TFL) -flap

- myofascial or myofascial cutaneous flaps
- pedicled TFL (Wangensteen 1934)
- free vascularized TFL (Hill et al.1979)


# Pedicled TFL

# TFL microvascular flap

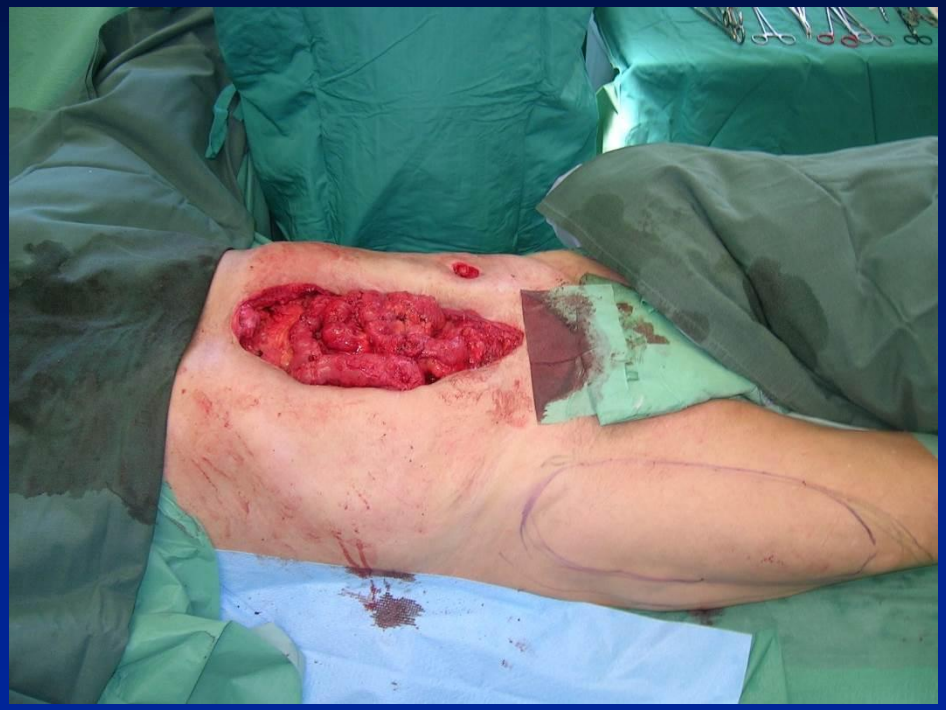

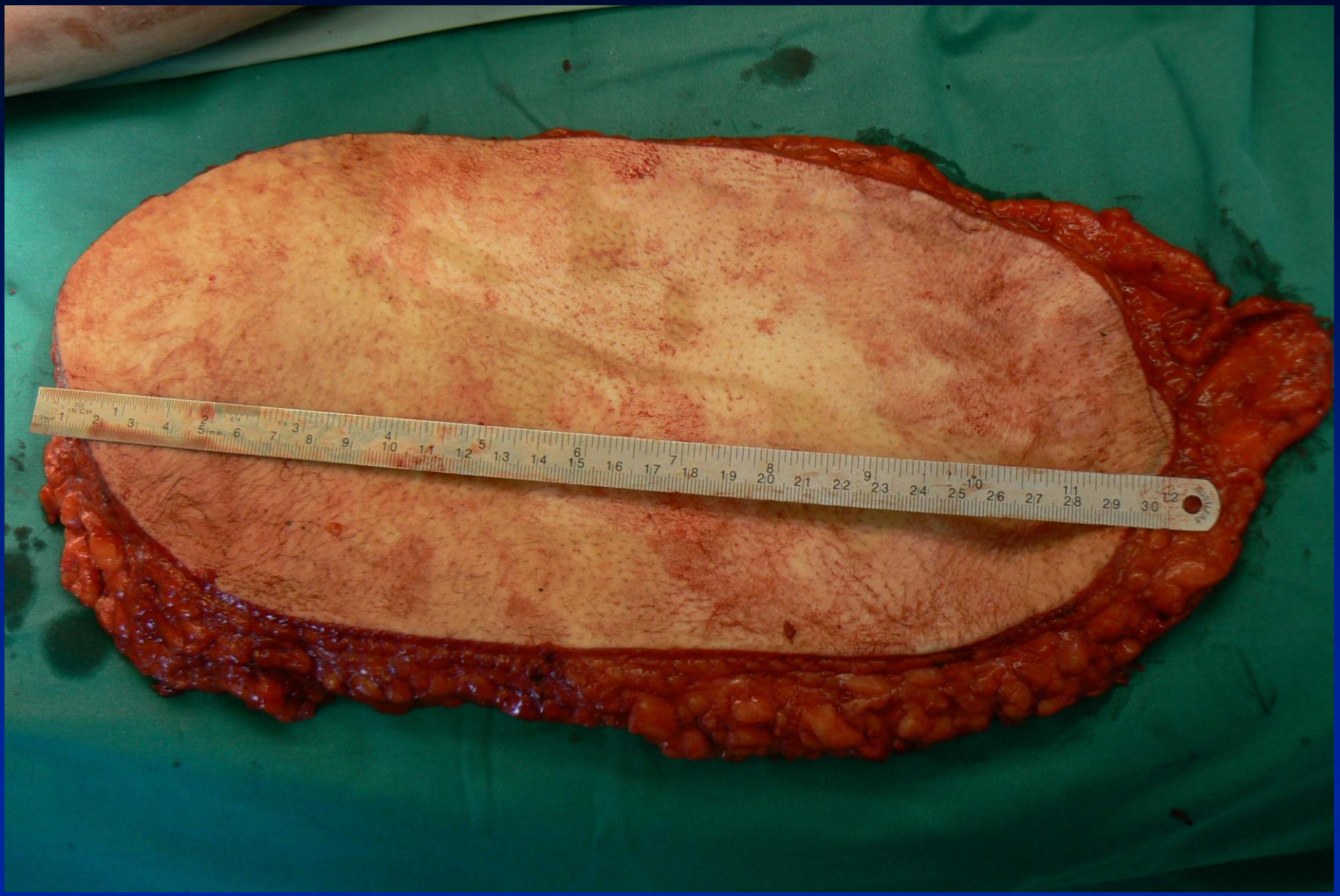

# Creating the vascular loop

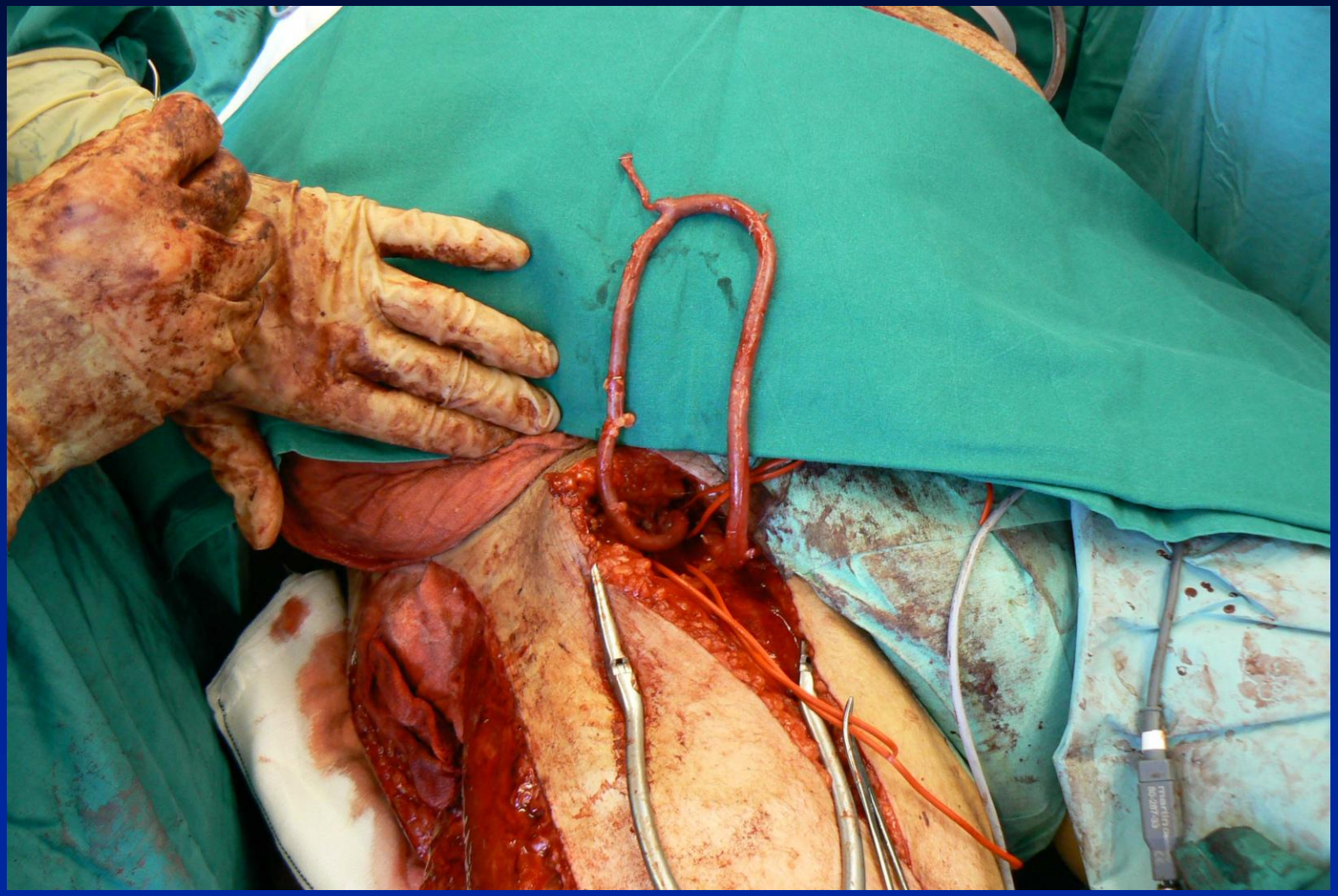

# Microvascular anastomosis

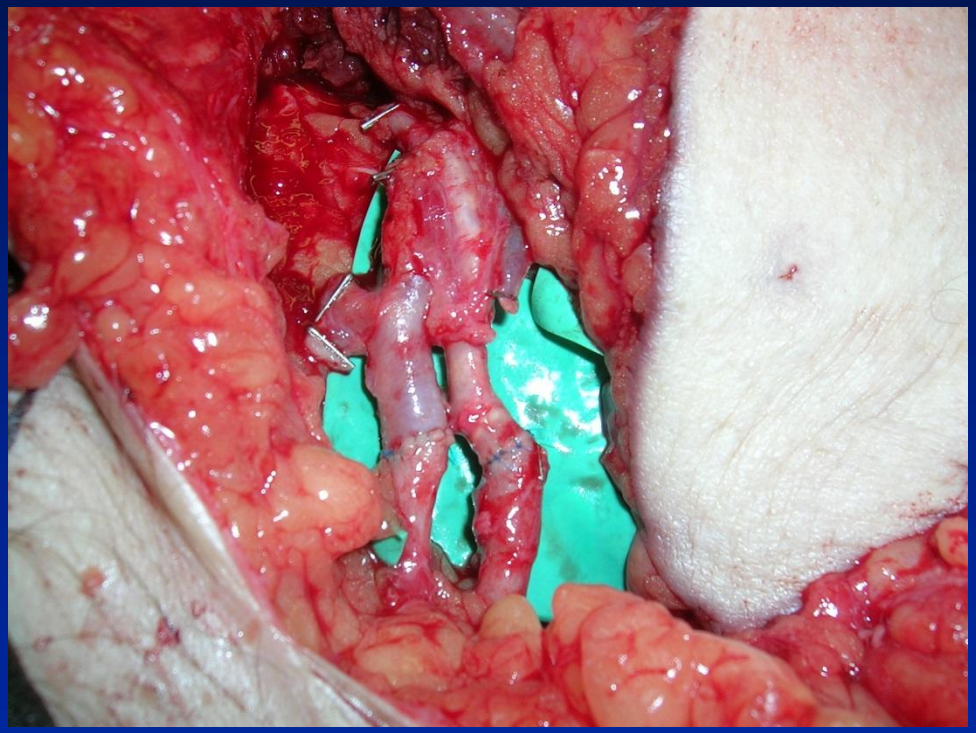

# Microvascular TFL-flap

- n = 20, mean age 52 (range 43-78) years
- mean follow up 5 (range 0.5-12) years

| | |
|---|---|
| - perioperative mortality | 0 |
| - total flap necrosis | 1 |
| - distal tip necrosis | 2 |
| - postoperative bleeding | 1 |
| - intra- abdominal infection | 0 |
| - deep surgical site infection | 0 |
| - hernia recurrence (after 3 months) | 1 |

Tukiainen and Leppäniemi 2011

# Management options (Leppäniemi & Tukiainen WJS 2011)

| *Defect* | *Primary* | *Addit/alternat.* |
|---|---|---|
| Small hernia, intact skin | | |
| No contamination | CS | Mesh (M) |
| Contamination | CS | Biological mesh (Mb) |
| Small hernia, grafted skin | | |
| No contamination | CS | +M or flap |
| Contamination | CS | +Mb or flap |
| Large hernia, intact skin | | |
| No contamination | CS | + flap or M |
| Contamination | CS | + flap or Mb |
| Large hernia, grafted skin | | |
| No contamination | Flap | + CS + M |
| Contamination | Flap | + CS + Mb |

# Case

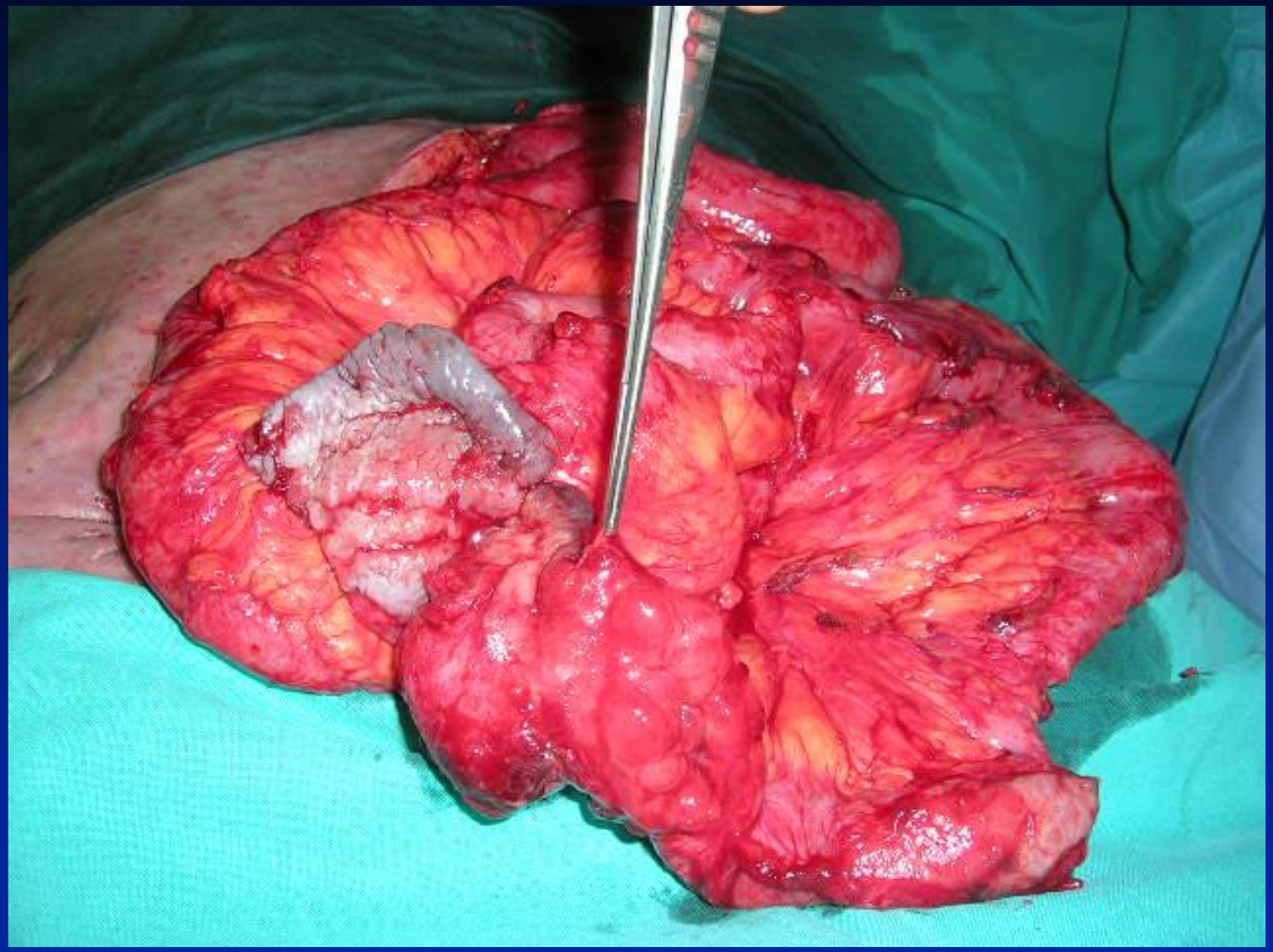

# Case 2: SSG day 15

# Case 2: 1 year later (not ready yet!)

# Case 2: 2 years later: Laparotomy (CS + biological mesh)

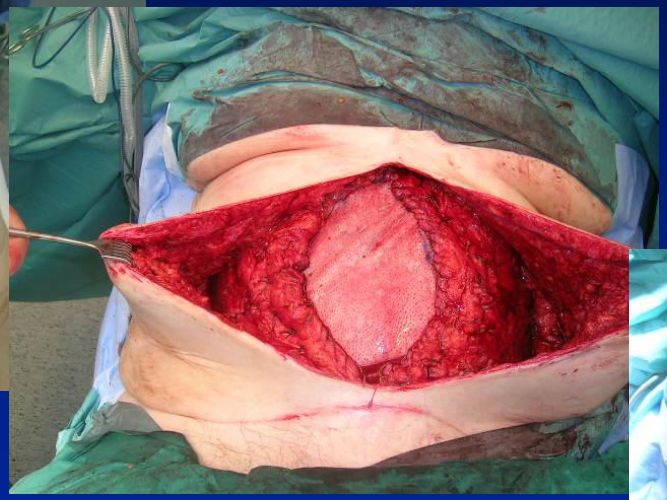

# Conclusions

- aim for early fascial closure after open abdomen
- when unable to close, think planned hernia at 3 weeks
- start with component separation
- be ready to use other options (mesh, flap) or a combination of techniques
- involve plastic surgeons early !

# Thank you !